

Equine Herpesviruses 1 and 4 (EHV-1/EHV-4)

EHV-1 and EHV-4 are ubiquitous double-stranded DNA viruses of the Alphaherpesvirinae family. Hallmark of these viruses is the establishment of a lifelong infection (carrier status). A virus reactivation and shedding in latent-infected horses with or without clinical signs is possible. Three main syndromes are described in connection with both viruses: rhinopneumonitis, late abortion/neonatal death, and myeloencephalopathy. EHV-4 is mostly responsible for upper respiratory airway diseases in young horses, whereas EHV-1 is mainly responsible for rhinopneumonitis, abortion, and myeloencephalopathy.

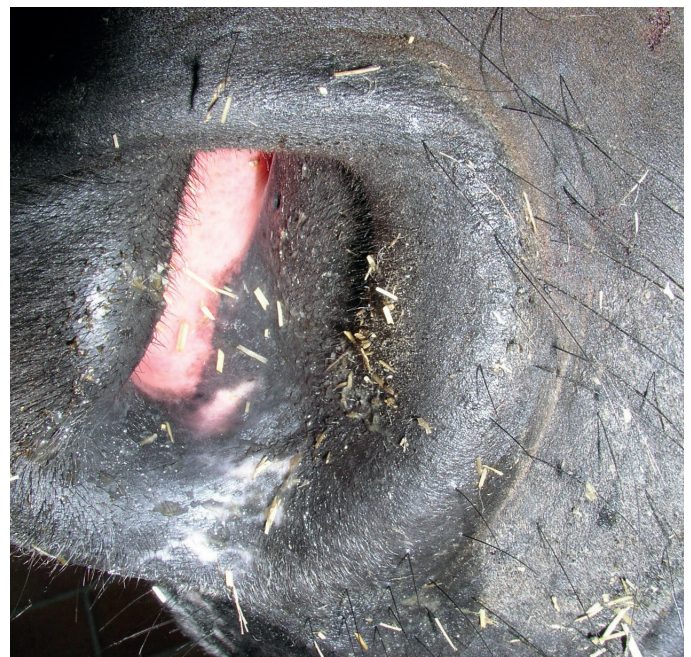Pathogenesis

Infection occurs through inhalation of viral particles or contact with contaminated tissue (e. g. abortion material), saliva, nasal or ocular discharge, and probably feces from virus-shedding carriers and horses with an active subclinical or clinical infection. Infection may be spread by contaminated hands and fomites (water, feeding bucket). Following inhalation, the virus replicates in the upper respiratory tract epithelial cells, producing death of cells and epithelial erosion. The virus spreads from cell-to-cell reaching the respiratory tract-associated lymph nodes within 24–48 hours. Following infection of leukocytes, a leukocyte-associated viremia is established, and it is responsible for the systemic spread of the virus to the central nervous system (CNS) and the pregnant uterus, among other tissues. Viremia persists for a week or longer and due to its high tropism for lymphocytes, the virus can also lead to immunosuppression.

Pathogenesis of EHV-related myeloencephalopathy and abortion is most likely related to the cell-associated viremia and its resulting infection of the endothelium. This in turn leads to vasculitis and reactive thrombosis, producing a general derangement of the microcirculation, local hypoxia—and consequently neuron death—and partial or absolute detachment of the placenta.

First-time infection occurs mostly within the very first weeks or months of life. Probably in almost all cases, a lifelong state of latency is established within the lymphoreticular system and trigeminal ganglion. Latently infected horses play a major role in the epidemiology of EHV-1 and EHV-4 infections: in stressful situations, such as transport, disease, and weaning, these animals may experience a viral reactivation, shedding the virus into their environment, thus enabling the outbreak of clinical disease without the introduction of new horses into the group. It is worth mentioning that the virus can be shed by horses showing clinical signs of disease or by asymptomatic cases.

The virus can be shed for up to 2–3 weeks after infection or reactivation. In cases of EHV-1 neurologic disease, the virus can be shed for an even longer period of time. Virus survival in the environment is estimated to be of about 14 days in most conditions.



Nasal discharge in a case of EHV-1 rhinopneumonitis
Courtesy of Equine Hospital Kottenforst/Germany

The virus has been isolated in semen of clinically healthy stallions. Although transmission through semen has not been documented, stallions may show scrotal edema, lower quality of semen and a lack of libido during EHV outbreaks.

After infection, immunity toward new infections is short (3–5 months). During this period, horses do not shed the virus and no viremia occurs after viral contact.

Respiratory tract disease

Clinical signs are observed between 2–10 days after infection or after a recrudescence episode in latent carriers. In most cases, infection is self-limiting and horses show mild clinical signs, if any (however, asymptomatic horses may still shed the virus into the environment). Most common clinical signs include pyrexia, depression, coughing, and serous to mucoid nasal discharge (mucopurulent in cases with secondary bacterial infection). Pharyngitis and tracheitis may also be present.

Some horses develop the so-called “poor performance syndrome” after infection with EHV-1/EHV-4, which is presumably attributable to a nonspecific bronchial hypersensitivity. Young naive foals are more clinically affected than older horses and develop a biphasic pyrexia for 8–10 days, nasal discharge, conjunctivitis, serous ocular discharge and progressive lymphadenopathy. In more serious cases, foals may experience respiratory distress and death. During perinatal infections, foals may show weakness and respiratory distress, and the infection may be fatal.

Abortion

Pregnant mares may experience a clinical or subclinical infection. The occurrence of viremia is the most important condition for uterus infection and placenta detachment. Therefore, a virus reactivation episode in latent-infected mares may probably also lead to abortion as well as a new viral infection or reinfection.

As a result of viremia, mares may experience an infection of endothelial cells leading to vasculitis, deranged placenta microcirculation, and transplacental virus spread. Fetal infection occurs in the course of virus translocation throughout the uterine-placental barrier, through blood-passage in the umbilical circulation, or by inhalation of infected amniotic fluid. Aborted fetuses are usually virus positive. Fetuses may be virus negative if placental necrosis/separation occurred before transplacental infection of the fetus.

EHV-1 abortion may occur at any stage of pregnancy. However, a virus-induced vasculitis seems to be more pronounced between the fifth and the ninth months of gestation, and 95 % of abortions caused by EHV-1 occur in the last trimester of pregnancy. This probably relates to a hormone-induced expression of virus adhesion molecules in the endothelium and leukocytes within the pregnant uterus. The aborted fetus is usually fresh, while minimal signs of autolysis can be present in some cases. A pronounced icterus is frequently observed and some foals may also have petechiation in the oral mucosa and nostrils. Placentae are often fresh but may show light edema. Increased fluid in the pericardial, thoracic, and abdominal cavities may be found, as well as mucosal hemorrhage of internal organs. Liver and spleen are frequently swollen with a brown or dark red color. Aborted foals, fetal membranes, and related tissues are a rich source of infectious virus.

Near-term infections may result in acute foal death after a few days due to fulminant viral pneumonia, hepatitis (icterus), and destruction of bone marrow.

Abortion may occur shortly after infection or some time thereafter, and mares usually do not show any premonitory clinical signs; nowadays, presentation as sporadic cases is more common but epidemic abortions still occur. It is important to note that abortion may also occur in regularly vaccinated mares. The virus remains within the genital tract shortly after abortion and in most cases the future fertility of the mare remains intact.

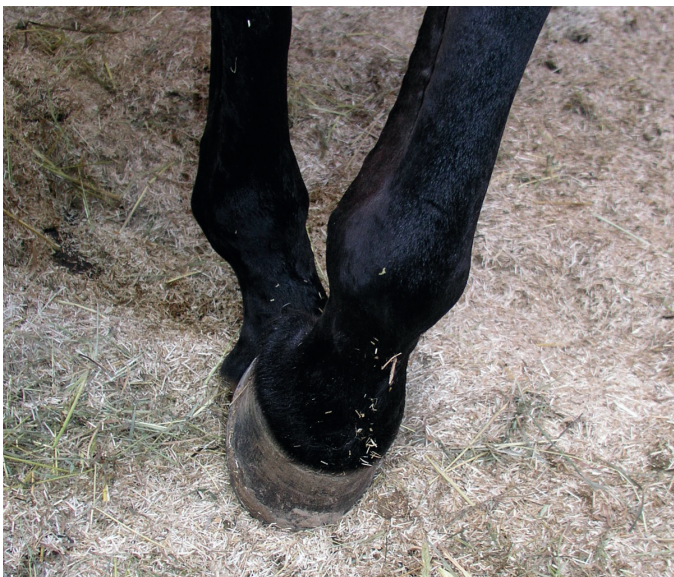Myeloencephalopathy

The EHV-1 induced myeloencephalopathy is rather an uncommon manifestation and may be observed in horses of different ages, in both males and females of any breed, as well as in barren or pregnant mares. However, some host factors like age, sex, pregnancy status, immunocompetence, and previous contact with the virus—as well as environmental and viral factors, like duration of viremia, viral load, and genetic variation of the virus—probably influence the clinical manifestation. The epidemiological presentation of disease may be sporadic or epidemic, and most cases are observed in late winter, spring, and early summer. The questions regarding why and when this cell-associated viremia leads to myeloencephalopathy have not been answered yet. A genetic strain of EHV-1 has been identified that contains a mutation that is highly associated with neurologic clinical signs. This neuropathogenic EHV-1 strain is detected more frequently in cases of myeloencephalopathy than in cases presenting with other clinical manifestations.

Detection of the mutated neuropathogenic strain indicates a significantly increased risk of developing myeloencephalopathy. However, the nonmutated wild-type strain can occasionally lead to EHV-1 induced myeloencephalopathy. Generally speaking, the clinical and epidemiological approach in isolated neurological cases and outbreaks should be the same, independent of the strain identified.

Infection of endothelial cells within the CNS appears to result in vasculitis, microthrombosis and migration of mononuclear cells with perivascular infiltration and local hemorrhage. This in turn leads to a disseminated ischemic necrosis of the spinal cord with degeneration and necrosis of the white matter and, to a lesser extent, the gray matter. The brain stem usually remains unaffected. Clinical signs are caused by ischemic lesions of CNS tissue and are not due to viral infection of CNS tissue; the correct term for this condition is therefore myeloencephalopathy and not encephalomyelitis. Morbidity of neurological cases in EHV-1 outbreaks varies greatly, but is usually about 10%.

Clinical signs appear 6–10 days after infection or reactivation of infection in latent carriers but can also present later on in the course of infection. Clinical signs may present without premonitory fever or signs of respiratory disease. Fever may appear but it goes usually unnoticed unless horses are checked on a regular basis. Most horses are normothermic and some may even be hypothermic. The severity of neurological clinical signs depends on the number, size, and location of neurologic lesions. Usually, a sudden onset of bilaterally symmetrical or asymmetrical ataxia of variable severity is observed, together with weakness of the fore- or hindlimbs, hypotonia of tail and anus, and a lack of perineal sensitivity. In general, pelvic limbs are affected earlier and more severely than the forelimbs. In mild cases, a proprioceptive insufficiency reflected in circumduction in one or several limbs, clumsiness, stumbling, toe dragging, and unwillingness to move are observed. Bladder atony with incontinence and difficulties to urinate may also be present. In more severe cases, horses may show a profound weakness of the limbs and even full paresis (with dog-sitting position), tetraparesis, and recumbency.



Diminished proprioception in a case of EHV-1 myeloencephalopathy

Courtesy of Equine Hospital Kottenforst/Germany

Nasal discharge, limb edema, colic, and anorexia can be concomitant clinical signs. Nasal discharge and coughing may appear days or even weeks before the presentation of typical CNS-related signs. Other abnormalities like mydriasis, hypopyon, uveitis, and optic neuritis have also been described. Signs related to cranial nerves dysfunction, like seizures, blindness, vestibular signs, and lingual, mandibular, and pharyngeal paresis (dysphagia), are rare. Depression is in most cases secondary to complications related to the overall infection process and not due to brain involvement. Signs of brain damage, like aberrant behavior and a low sensorium, are very rare.

EHV-1 myeloencephalopathy should always be considered a potential diagnosis if in the short-term several cases with weakness, ataxia, pyrexia, respiratory disease, or abortion are observed. It should be noted that clinical signs may greatly vary. Horses with mild neurological signs tend to stabilize within hours or a few days and usually show a complete recovery. Recumbent horses may develop secondary complications (myopathy, pneumonia, colic, bladder rupture, etc.) with a poor prognosis.

Diagnosis

Diagnosis of EHV-1/EHV-4 infections should be based on a complete history, the epidemiological hallmarks of each case, physical examination, and laboratory tests. The choice of the correct test in the right stage of disease is of paramount importance for an accurate diagnosis.

Nonspecific changes on initial diagnostics

CBC

In an active viral infection, there are mostly nonspecific changes. A transient leukopenia (lymphopenia) is observed within the very first days of infection. As infection progresses, a leukocytosis (lymphocytosis) may develop.

Cerebrospinal fluid (CSF)

In an active EHV-1 infection, CSF total protein may be increased with or without a concomitant increase of the total nucleated cell concentration. Moreover, xanthochromia may be present as a result of altered endothelial properties.

Specific diagnostic testing

RealPCR

Real-time PCR detecting viral DNA in respiratory specimens, whole blood, CSF fluid, or reproductive/abortion specimens offers a reliable, sensitive, and rapid diagnostic tool. A positive equine herpesvirus (EHV-1 or EHV-4) RealPCR™ result can help you confidently:

- Diagnose horses exhibiting clinical signs consistent with EHV disease.
- Diagnose horses exposed to confirmed EHV cases.
- Isolate infected or exposed horses from other susceptible horses in a timely manner.
- Identify mutated EHV-1 strains that are more likely to result in neurological clinical manifestations.

Respiratory specimens

In respiratory disease, abortion and myeloencephalopathy, the virus is usually shed for about 10 days (seldom for up to 3 weeks) after infection or reactivation of virus in latent carriers. The specimen should be obtained in the early stages of disease. A negative result does not rule out an EHV infection. The highest virus shedding from the nasal mucosa usually occurs during the first fever peak.

EDTA whole blood

A positive EHV result in a whole blood specimen is indicative of an EHV-related viremia. The specimen should be taken during a fever episode (viremia) or shortly thereafter. A positive result is indicative of viral infection in a patient with clinical signs. Viremia usually occurs during the second fever peak in the course of infection.

The submission of both whole blood in EDTA and a nasal swab is recommended.



Abortion specimens

In cases of abortion, fetal and placental tissue should be submitted in addition to reproductive tract swabs and whole blood from the affected mare.

In some cases, clinical signs are observed several days after infection. In these cases, viral DNA may not be detected in nasopharyngeal swabs or blood at the time of presentation of clinical signs (e.g., in cases of abortion). The virus may be shed in cases of other diseases not related to these viruses.

Serology

Quantitative detection of antibodies by virus neutralization offers a retrospective diagnostic tool but may not be positive early in infection. Paired serum specimens taken 2–3 weeks apart are recommended, **and the first specimen must be obtained in the early stages of disease. Ideally, both specimens should be tested at the same time. For this purpose, keep the first serum specimen frozen and send it together with the second specimen to be analyzed.**

Recent contact with the virus is suspected with seroconversion or if at least a four-fold increase of antibodies is detected.

A positive titer in a single specimen indicates merely a previous exposure to the virus and/or that the horse has been vaccinated. The antibody titer does not correlate to the degree of protection against infection nor to the degree of viremia.

In cases of abortion, viral infection may have occurred weeks or even months before onset of clinical signs. In these cases, no significant antibody increase will be detected in the paired serum specimens, as serum is obtained at the time of presentation of clinical signs.

Differential diagnosis

All other forms of respiratory disease, including viral (e.g., influenza virus, viral arteritis) and bacterial infections are potential differential diagnoses. The same applies for other causes of neurological impairment, like cervical vertebral instability, stenotic myelopathy, cervical vertebral or CNS trauma, polyneuritis equi, aberrant parasite migration, degenerative myelopathy, intoxications, botulism, etc. Other infectious causes of abortion, like leptospirosis, viral arteritis, and others should also be considered. In foals, other differential diagnoses are neonatal septicemia, viral arteritis, neonatal maladjustment syndrome, and neonatal nutritional myodegeneration syndrome.

Treatment

There is no specific treatment available for EHV-1/EHV-4 infections, only supportive symptomatic alternatives. Respiratory disease is often self-limiting and requires mostly general nursing support. It is important to note that affected horses are a source of infectious virus and should, therefore, be housed and managed individually.

In cases of myeloencephalopathy, therapeutic options are unfortunately quite limited. Recumbent patients should have enough bedding in the stable, which should be in a quiet area. Sedation, IV fluid therapy, and parenteral nutrition may be necessary. Special care should be taken to avoid decubital ulcers and impaction colic. Regular bladder and rectal evacuation may be necessary. In cases of impaired bladder function, an indwelling Foley catheter may be needed. It is important to keep it under aseptic conditions to avoid secondary infections. Skin-protective ointments (e.g., petroleum jelly) should be applied in the perineal area to avoid urine scalding.

Horses in the convalescent phase should be rested for about 3 weeks after clinical signs subside.

The most important medication for the symptomatic treatment of EHV infections is presented below. Different medications may be used according to the clinical signs and the current stage of disease.

Corticosteroids

Corticosteroids have strong anti-inflammatory and antioxidant effects. In cases of myeloencephalopathy, corticosteroids may be appropriate, as they may limit the degree of thromboischaemic lesions caused by infection of endothelial cells. Corticosteroids should be prescribed with caution. However, the risk of a viral reactivation (viremia) due to the administration of corticosteroids seems to be low. Corticosteroid treatment for more than 5 days may interfere with the tissue regeneration process.

Nonsteroidal anti-inflammatory drugs (NSAIDs)

NSAIDs play an important role as antipyretic and prostaglandin blocking agents. Furthermore, they can reduce thrombocyte aggregation during vasculitis at the CNS level. Aspirin should not be administered in cases of myeloencephalopathy, due to the high risk of hemorrhage associated with its use.

Antibiotics

Due to immunosuppression, antibiotics may be administered in cases of secondary bacterial infection of the upper respiratory tract, when a urinary bladder catheter is placed for a long period of time, in cases with decubital ulcers, etc. However, antibiotics are not necessary in all cases.

Dimethyl sulfoxide (DMSO)

DMSO is a free radical scavenger and may inhibit thrombocyte aggregation. Treatment with DMSO infusion has been described in cases of neurologic disease. Due to its potential teratogenic effect, DMSO should not be used in pregnant mares.

Sympathomimetics

Sympathomimetic drugs, like clenbuterol, may increase the mucociliary clearance and reduce contamination of the respiratory airways.

Mucolytics

Mucolytic agents can be used in cases of rhinopneumonitis.

Antioxidants

The positive effects of vitamin E in inflammatory processes can be favorable at any stage of disease. However, the necessary concentration within CNS tissue may be achieved only after several days.

L-Lysine

L-Arginine is an important amino-acid necessary for herpes viral replication, whereas L-Lysine inhibits intestinal absorption of L-Arginine. L-Lysine is a component of several food stuff additives and seems to have a stronger therapeutic effect within the very first stages of infection. In cases of neurologic disease, L-Lysine seems to be of limited efficacy.

Antiviral drugs


Second-generation nucleoside analogues, like acyclovir, valacyclovir, or gangaclovir, have no effect during latent infections, because of the lack of expression of viral genetic replication material. Several features related to these drugs, such as their efficacy during an active infection, dose, potential side effects, and development of resistance require further investigation before a clear indication for its use can be made.

Prevention and control

Due to the characteristics of viral transmission and pathogenesis, prevention and control of infection and outbreaks are difficult tasks. Equine herpesviruses 1 and 4 are enzootic in the equine population worldwide with a very high prevalence. Outbreaks may present a high morbidity and, under certain circumstances, high lethality. General control measures have three main aims:

1. Prevention of disease entrance onto sites (difficult!).
2. Limit dissemination of infection and severity of clinical cases after the onset of active infections.
3. Limit viral spread to other premises.

However, good management practices together with strict hygiene measures offer a good basis for disease control. Abortion material is a rich source of infectious virus and should be collected, dealt with and disposed appropriately. Sick horses should be kept in isolation facilities. Separate equipment and persons should be used for healthy and affected equines. A regular and consistent vaccination program of all equines within a premises, including pregnant mares, is recommended in order to achieve a high general immunity. Combination vaccines can be used in order to comply with current regulations regarding influenza vaccination. Vaccination does not prevent clinical infections in every case, nor does it prevent the establishment of viremia and latent infections (carriers), but vaccinated horses seem to have a shorter period of viral shedding after infection. Vaccination in an EHV-1 outbreak is controversial, and many authors discourage this practice. Immunostimulants can be administered to healthy horses in stressful situations or during outbreaks.



Diagnostic options

When to use	Test name and components	Test code
Screening of nonclinical or clinical horses with known exposure to equine herpesvirus (EHV)	Equine Herpesvirus Types 1 (EHV-1) and 4 (EHV-4) RealPCR™ Tests 2–11 Specimens 12 or More Specimens Equine herpesvirus type 1 (EHV-1; includes identification of wild-type and mutated neuropathogenic strains) and equine herpesvirus type 4 (EHV-4) RealPCR™ tests	2699 26692 26693
Horses with neurological clinical signs compatible with equine herpesvirus myeloencephalopathy (EHM)	Equine Neurologic Disease Panel Equine protozoal myeloencephalitis (EPM) by Western blot (serum), West Nile virus IgM antibody by capture ELISA, equine herpesvirus type 1 (EHV-1; wild-type and mutated neuropathogenic strains) RealPCR™ tests	2619
Comprehensive testing for horses with respiratory signs and unknown exposure history	Equine Respiratory RealPCR™ Panel (Comprehensive) Equine adenovirus, equine influenza virus (EIV/H3N8), equine herpesvirus type 1 (EHV-1; wild-type and mutated neuropathogenic strains), type 2 (EHV-2), type 4 (EHV-4), and type 5 (EHV-5); equine rhinitis A virus (ERAV); equine rhinitis B virus (ERBV); <i>Streptococcus dysgalactiae</i> subsp. <i>equisimilis</i> ; <i>Streptococcus equi</i> subsp. <i>equi</i> ; and <i>Streptococcus equi</i> subsp. <i>zooepidemicus</i> RealPCR™ tests. Includes culture (organism ID only) on selective media for β-hemolytic <i>Streptococcus</i> spp.	3324
	Equine Respiratory RealPCR™ Panel (Standard) Equine influenza virus (EIV/H3N8), equine herpesvirus type 1 (EHV-1; wild-type and mutated neuropathogenic strains) and type 4 (EHV-4), <i>Streptococcus dysgalactiae</i> subsp. <i>equisimilis</i> , <i>Streptococcus equi</i> subsp. <i>equi</i> , and <i>Streptococcus equi</i> subsp. <i>zooepidemicus</i> RealPCR™ tests; includes culture (organism ID only) on selective media for β-hemolytic <i>Streptococcus</i> spp.	2740
Comprehensive testing for horses with history of abortion and unknown exposure history	Abortion/Postpartum Sick Mare RealPCR™ Panel—Equine <i>Amycolatopsis</i> spp., <i>Bartonella</i> spp., <i>Candida albicans</i> , <i>Crossiella equi</i> , equine herpesvirus type 1 (EHV-1) and type 4 (EHV-4), <i>Leptospira</i> spp., <i>Salmonella</i> spp., <i>Streptococcus dysgalactiae</i> subsp. <i>equisimilis</i> , and <i>Streptococcus equi</i> subsp. <i>zooepidemicus</i> RealPCR™ tests	3558
Treatment monitoring of EHV-1 confirmed horses	Equine Herpesvirus Type 1 (EHV-1) RealPCR™ Test 2–11 specimens 12 or More Specimens Includes identification of wild-type and mutated neuropathogenic strains	2566 25662 25663

Specimen requirements

7 mL EDTA whole blood and/or deep nasopharyngeal swabs; keep refrigerated. Nasal swabs are used to detect animals shedding the virus or that were recently exposed to a confirmed case. A whole blood specimen is recommended from a symptomatic animal to detect viremia. Submission of both specimen types for EHV RealPCR testing is ideal. For nasopharyngeal swabs, please submit dry, plastic-stemmed swabs, without transport media, in an RTT or WTT (plain plastic tube); keep refrigerated.

For equine neurologic panel submissions, also include 2 mL serum (no hemolysis or lipemia) for serology.

For respiratory disease panel submissions, deep nasopharyngeal swabs (one from each nostril) are the preferred specimen type and should be collected prior to antibiotic administration. For culture, please submit an additional culture swab in transport media.

For abortion/postpartum mare panel submissions, recommended specimens are the following: endometrial swab or endocervical brush, swab from clitoral fossa and sinus, and 2 mL EDTA whole blood (LTT); keep refrigerated. If available, also include 2 mL (0.1 mL minimum) umbilical cord blood (LTT), fresh placental tissue (from cotyledons), fresh fetal spleen, fresh fetal lung, and/or 2 mL fetal stomach contents. Submit tissue, fluids, and dry, plastic-stemmed swabs, without transport media, in RTTs or empty, sterile containers. Submit placental tissue and fetal specimens in separate containers and label as “fetal” or “placental.” Place separate fetal and placental containers together into a single bag and submit with a single requisition form. Collect specimens prior to antibiotic administration.

Turnaround time: 1–4 days for RealPCR tests; allow additional time for culture or serology

Ordering your tests online

Did you know that you can search for diagnostic tests, create requisitions, and review status and results on vetconnectplus.com?

Customer support services

IDEXX supports your practice with our customer support, technical support, and medical consulting services teams, including our diagnostic support veterinarians and board-certified veterinary specialists.

1-888-433-9987