

Diagnostic update

Faecal Dx antigen testing has been expanded to include *Cystoisospora* spp. detection.

To ensure the health of patients, a faecal examination for intestinal parasites is an important part of routine wellness care as well as those with gastrointestinal disease.

Regardless of the faecal procedure used, there can be some limitations on accurately identifying infections with some parasites. Detection of common parasites can be difficult with the current diagnostics. IDEXX Reference Laboratories offers Faecal Dx® antigen testing as an additional tool for detecting these parasites. With the addition of *Cystoisospora* spp. antigen detection (formerly known as *Isospora*), Faecal Dx profiles now provide more accurate detection of the most common and clinically relevant intestinal parasites.

Background

In small-animal practice, nematodes, cestodes, and coccidia protozoa are commonly encountered intestinal parasites in canine and feline patients. They each have a unique life cycle, and their prepatent period, the time in which they infect a host before laying eggs seen in the faeces, is unique to each parasite. This prepatent period may allow infections to go undetected on faecal ova and parasites (O&P) testing, increasing the chance for the appearance of clinical signs prior to evidence of eggs, oocysts, or proglottids in the faeces. The prepatent period is 4–13 days for most species of *Cystoisospora* in dogs and cats.¹ *Cystoisospora* spp. can cause coccidiosis in both dogs and cats.²

Prevalence

Infections are considered common in both dogs and cats, with various surveys indicating presence in 2.9%-7% of dogs and 2%-15.7% of cats in Australia,³ depending on the population tested.

Two publications assessing IDEXX fecal testing over a 3-year period determined that *Cystoisospora* is found in 1.6% of dogs and 2.2% of cats presented for wellness visit, with positive results most commonly found in puppies and kittens less than 6 months of age.^{4,5}

Clinical signs

Healthy adult dogs and cats may be infected and show no clinical signs. Clinical signs are more likely in young, immunocompromised, and/or stressed patients and include diarrhoea, weight loss, dehydration, haemorrhage, vomiting, depression, and anorexia.²

Infections left untreated can be potentially fatal. Infections usually occur at 3–8 weeks of age, with the majority of clinical cases diagnosed in puppies/kittens less than 4 months old.² In immunocompetent adult animals, infection very rarely causes disease. Adults may shed oocysts for a few days and have no clinical signs.¹

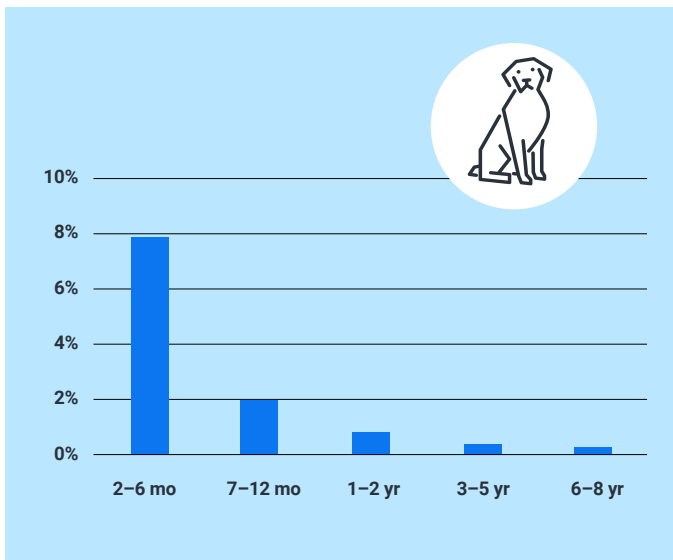


Figure 1. Canine *Cystoisospora* spp. positivity by faecal O&P testing.⁴

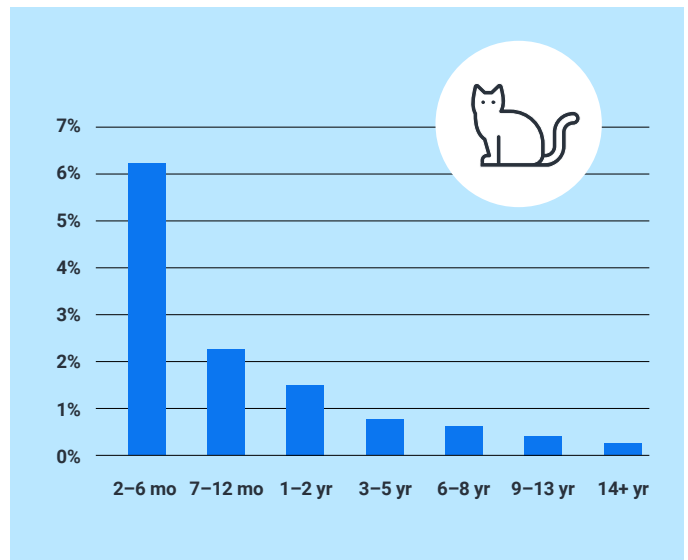


Figure 2. Feline *Cystoisospora* spp. positivity by faecal O&P testing.⁵

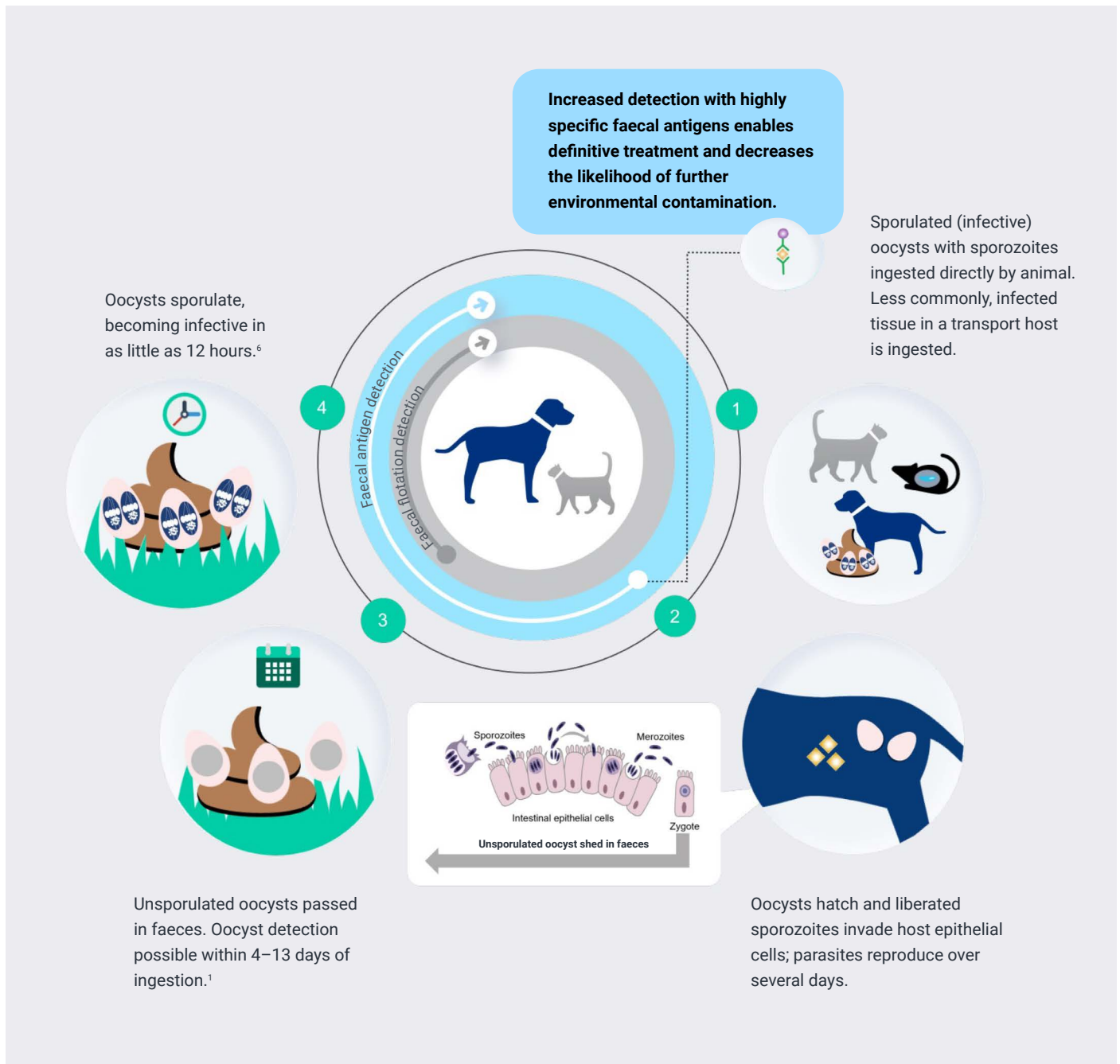

Figure 3. *Cystoisospora* life cycle.

Current diagnostics¹

Historically, diagnosis of canine and feline coccidiosis is based on signalment, history, and clinical signs, and the oocysts present in faeces. Faecal examination should be performed using centrifugal flotation and a sufficient volume of faeces. The presence of oocysts in faeces alone is not proof that coccidiosis is the cause of clinical signs. Oocysts of *Eimeria* spp. are sometimes observed in canine faecal specimens because of coprophagy of avian,

rabbit, rodent, or ruminant faeces. Dogs and cats are not hosts to *Eimeria* spp. These oocysts are referred to as pseudoparasites. These oocysts never reach the two-celled stage typical of *Cystoisospora* spp. Additionally, oocysts of many *Eimeria* spp. often have oocyst wall ornamentations called micropyles or micropyle caps.

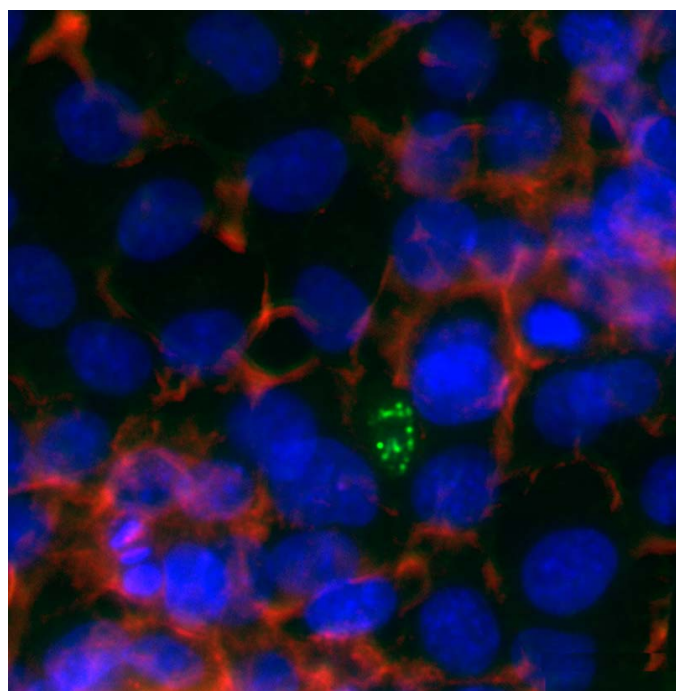
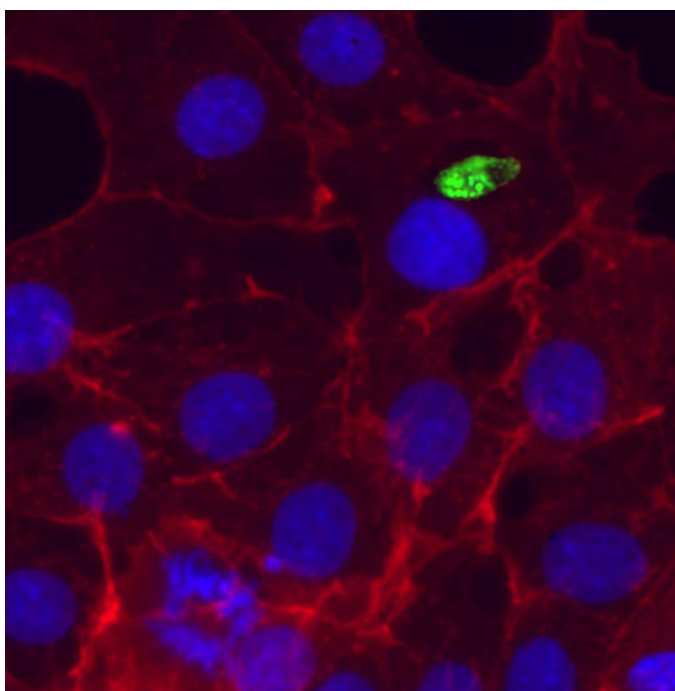


Figure 4. Immunofluorescent images of *Cystoisospora*-infected canine cell model at 3 days postinfection. Shown in green are antigen-positive *Cystoisospora* sporozoites embedded in canine cells. Cultures were counterstained to show cytoskeletal architecture in red and nuclei in blue.

Testing innovations

With the addition of *Cystoisospora* antigen to Faecal Dx® panels and profiles, detection does not depend on the presence of oocysts in the faeces. The coproantigen is detected from sporozoites, merozoites, and oocysts in canine and feline faecal specimens. The coproantigen is specific to pathogenic *Cystoisospora* spp. of both dogs and cats, including *C. canis*, *C. felis*, *C. rivolta*, and *C. ohioensis-like* complex. It does not cross-react with other coccidia, such as *Eimeria* spp., which can be commonly found in faeces as a result of coprophagy.

In 86,836 faecal specimens submitted to IDEXX Reference Laboratories over a 2-week period, 2.7% were positive for antigen, while only 1.0% were positive for *Cystoisospora* oocysts by faecal O&P. The presence of antigen shows 89% (86%–91% CI) positive and 98% (98.05%–98.24% CI) negative agreement with faecal O&P. Based on seasonal trends, we would expect approximately 2.6%–3.7% of specimens to be antigen positive.⁷ As with faecal O&P, we see more than 8.0% positivity in dogs and cats less than 6 months of age, with positive results much less common in older pets.

Treatment

Sulfadimethoxine is the only drug that is label approved for treatment of enteritis associated with coccidiosis. A number of drugs that have coccidiocidal activity, are approved in other species, and have been shown to be effective in dogs and cats when used extra label, including ponazuril, toltrazuril, and diclazuril.² In addition to treatment, appropriate sanitation is helpful in preventing spread of coccidiosis in kennels and catteries. Oocysts sporulate quickly in the environment, and daily removal of faeces can aid in the prevention of coccidiosis. Treatment of all in-contact animals may also be beneficial in controlling coccidiosis in kennels. Prevention of predation should be emphasized to prevent infection via ingestion of infected tissue from paratenic hosts.¹



References

1. Companion Animal Parasite Council. CAPC Guidelines: Coccidia. Updated October 1, 2016. Accessed February 8, 2024. www.capcvet.org/guidelines/coccidia
2. Dubey JP, Greene CE. Enteric coccidiosis. In: Sykes JE, Greene CE. *Infectious Diseases of the Dog and Cat*. 4th edition. Saunders; 2012:828–833.
3. Carlisle S, Palmer R, Thompson A, Rebecca J, Traub R, Robert Rees, Ian D. Robertson, National study of the gastrointestinal parasites of dogs and cats in Australia, *Veterinary Parasitology*, Volume 151, Issues 2–4, 2008, Pages 181-190, ISSN 0304-4017, <https://doi.org/10.1016/j.vetpar.2007.10.015>.
4. Sweet S, Hegarty E, McCrann DJ, Coyne M, Kincaid D, Szlosek D. A 3-year retrospective analysis of canine intestinal parasites: fecal testing positivity by age, U.S. geographical region and reason for veterinary visit. *Parasit Vectors*. 2021;14(1):173. doi:10.1186/s13071-021-04678-6
5. Sweet S, Szlosek D, McCrann D, Coyne M, Kincaid D, Hegarty E. Retrospective analysis of feline intestinal parasites: trends in testing positivity by age, USA geographical region and reason for veterinary visit. *Parasit Vectors*. 2020;13(1):473. doi:10.1186/s13071-020-04319-4
6. Lappin MR. Isosporiasis. In: Sykes JE, ed. *Canine and Feline Infectious Diseases*. WB Saunders; 2014:793–796. doi:10.1016/B978-1-4377-0795-3.00082-X
7. Data on file at IDEXX Laboratories, Inc. Westbrook, Maine USA.